



TELECYTOLOGY

## Specialty Services

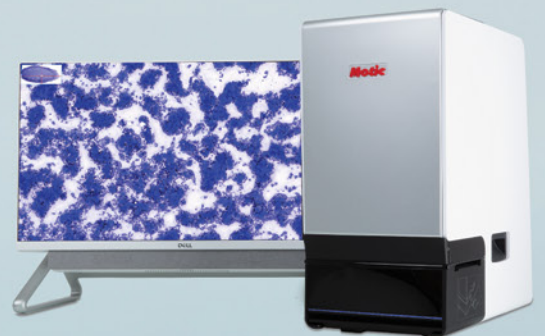Clinical Pathology in your practice... on demand! Wield the power of digital telecytology with our global team of board-certified clinical pathologists.

Comprehensive reports in minutes

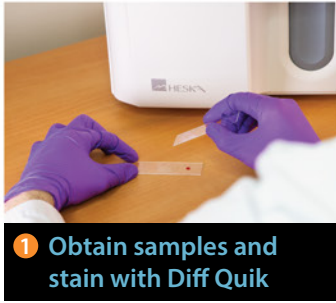STAT service

Real-time chat support

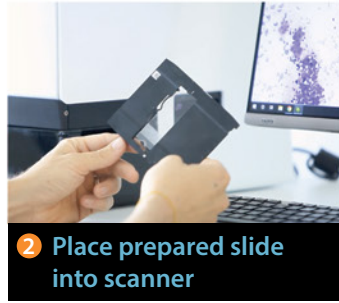
Board-certified clinical pathologists



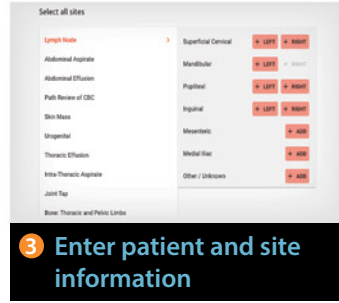
# Easy Operation



1 Obtain samples and stain with Diff Quik



2 Place prepared slide into scanner



3 Enter patient and site information



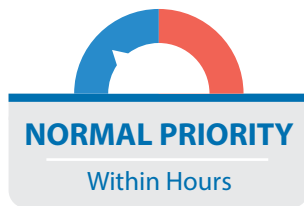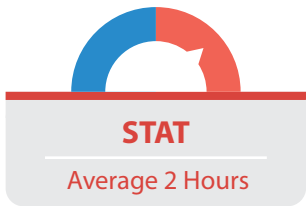
Pathologist review and report

## The HeskaView Telecytology™ Advantage

- Elevate standard of patient care
- Expedite client communication
- Eliminate delays in slide review
- Move on to next step diagnostics and treatment same day



## Turn-around time options...



## Add a specialty service to your practice without hiring a specialist!

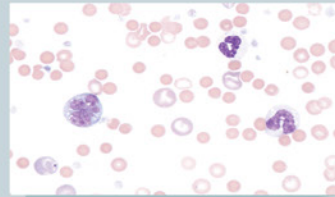
Digital telecytology allows timely access to veterinary clinical pathologists who can assist with diagnostic evaluation of your patients. Choose STAT\* or Normal Priority<sup>S</sup> turn-around time options. Whether you are a cytology novice or expert, the board-certified pathologists at HeskaView Specialty Services can help with everything from blood smears to fine needle aspirates to pre-surgical planning and more.

### Examples of Submissions

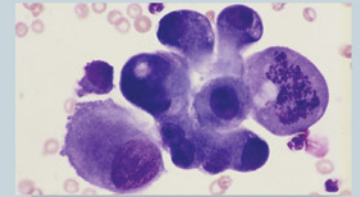
- CBC Pathology Review
- Dermal & Subcutaneous Masses
- Lymph Nodes
- Body Cavity Effusions
- Joint Taps
- Oral & Nasal Masses
- Abdominal Organs & Masses
- Thoracic Organs & Masses
- BAL/TTW
- Urogenital Cytology
- Vaginal Cytology
- Bone Lesions
- Bone Marrow Cytology
- CSF Cytology and more...

Start diagnosing at the speed of digital today.

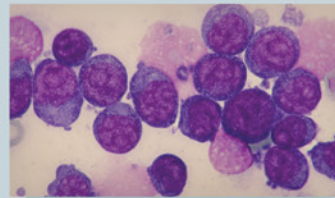
## Get answers to difficult and time-consuming cases



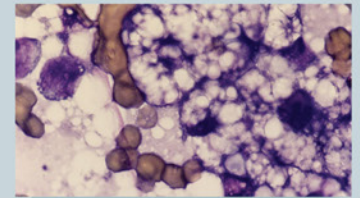
4 year old M/C Cocker Spaniel – peripheral blood film:  
**Immune mediated hemolytic anemia?**



12 year old F/S DSH – 1.5 cm round, firm mass near the angle of the jaw:  
**Cancer or inflammation?**



6 year old M/C GSD – 3.5 cm round, soft mass in submandibular space:  
**Lymphadenitis, lymphoma, or sialocele?**



8 year old F/S DSH – hepatomegaly and increased liver enzymes:  
**Hepatic lipidosis or cancer?**



\*For preliminary interpretation. Additional STAT charges apply. <sup>S</sup>Average turnaround times may vary. Longer turnaround times may be experienced during peak submission times, overnights and on weekends. ©2024 Heska Corporation. All Rights Reserved. Specifications and appearance may be changed without notice. Antech, the Antech logo, and all other trademarks used herein are the registered trademarks of Antech Diagnostics, Inc. or its affiliates. Motic is a registered trademark of Motic Instruments Inc. US21LT0204\_009 110524