

Bella

11-year-old | Female Spayed | Golden Retriever | 53 lbs

Cancer Screening in a Geriatric Golden Retriever

ONCOK9 by PetDx

Presentation

USE CASE

Screening

- ✓ Age 7 and Older
- ✓ Breed Predisposed to Cancer

CLINICAL DETAILS

Bella presented for a routine wellness visit. Her physical exam showed no clinical signs of cancer.

WHY ONCOK9 WAS PERFORMED

Bella had no signs of cancer but was over age 7 and of a predisposed breed. OncoK9 was performed as part of her wellness and preventive care evaluation.

OncoK9® Result

CANCER SIGNAL



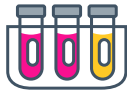- A *Cancer Signal Detected* result significantly increases the likelihood that cancer is present, but does not confirm the presence of cancer. **This result should not be used as the sole basis for making important decisions such as treatment or euthanasia.**
- A confirmatory cancer evaluation should be performed to establish a definitive diagnosis.

Due to a **Cancer Signal Detected** OncoK9 result, a Confirmatory Cancer Evaluation was performed.

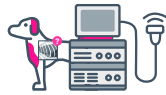Confirmatory Cancer Evaluation



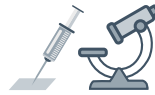EXAM



LABORATORY



IMAGING



SAMPLING

Cancer Workup & Findings

- Abdominal ultrasound – hypoechoic mass in the liver; mottled spleen and liver
 - When shaving for ultrasound, multiple red-black miliary skin lesions noted
- Oncologist visit scheduled 4 weeks out
- Additional dermal lesions developed while awaiting oncology appointment
 - Biopsied lesions (pinna + perianal area + ventrum)

Diagnosis from histopathology: Hemangiosarcoma

Case Takeaways/Outcome

VETERINARIAN


OncoK9 detected the presence of cancer in a patient with no clinical signs, and helped shorten the path to diagnosis by providing lead time for imaging scheduling.

OWNER

OncoK9 gave Bella's owners the time to prepare and the option to start therapy.

PATIENT

Bella was able to get started on therapy prior to developing clinical signs, potentially giving her prolonged good quality of life.



Bella

11-year-old | Female Spayed | Golden Retriever | 53 lbs

Cancer Screening in a Geriatric Golden Retriever

ONCOK9[®] by PetDx[®]

Case Summary

- 11yo FS asymptomatic Golden Retriever with no suspicion of cancer
- OncoK9[®]: **Cancer Signal Detected**
- Confirmatory Cancer Evaluation recommended
- Skin masses & miliary red-black skin nodules noted, confirmed to be hemangiosarcoma on histopathology
- Client pursued oncology consultation and elected to begin palliative care

ONCOK9[®] by PetDx[®]

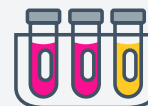Confirmatory Cancer Evaluation

May include any or all of the following:



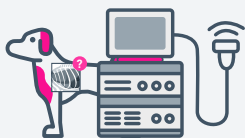
EXAM

- Thorough clinical history
- Thorough physical exam
 - Including oral and rectal exam



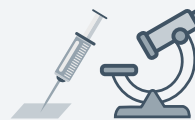LABORATORY

- CBC and Chemistry
- Urinalysis



IMAGING

- Thoracic radiographs – 3 views
- Abdominal imaging – ultrasound preferred
- Radiographs of localized areas of bone or joint pain, if present



SAMPLING

- Tissue sampling of any detected masses or enlarged lymph nodes for pathological analysis

In some cases, advanced imaging (such as CT and/or MRI) may be indicated.



Scan the QR code or visit petdx.science/case-studies to browse additional case studies.

✉ sales@petdx.com ☎ (833) 464-7297 🖱 www.petdx.com